

Marta Osypińska

Animal Bones from the Excavations at El-Zuma

Polish Archaeology in the Mediterranean 16, 404-408

2005

Artykuł został opracowany do udostępnienia w internecie przez Muzeum Historii Polski w ramach prac podejmowanych na rzecz zapewnienia otwartego, powszechnego i trwałego dostępu do polskiego dorobku naukowego i kulturalnego. Artykuł jest umieszczony w kolekcji cyfrowej bazhum.muzhp.pl, gromadzącej zawartość polskich czasopism humanistycznych i społecznych.

Tekst jest udostępniony do wykorzystania w ramach
dozwolonego użytku.

ANIMAL BONES FROM THE EXCAVATIONS AT EZ-ZUMA

Marta Osypińska

Animal bones were part of the assemblage recovered during the first season of excavations at the cemetery in ez-Zuma. 84 fragments, which came from the three chambers of Tumulus 2,¹ were examined.

Generally, the bones were in very good condition with most being preserved complete. Any crumbling or breaking occurred during the lifting and moving of the material and was due to its considerable fragility caused by substantial loss of collagen as a result of the extremely dry conditions of deposition. Consequently, taxonomic and anatomic determination was possible in the case of 79 bones and fragments of bones (see tables below). The five pieces that avoided identification for lack of diagnostic features can be safely assumed to be camel long bone fragments.

Remains of two mammal species and one bird bone were recorded. The two identified species were human-bred animals: sheep *Ovis aries f. domestica*, and camel *Camelus dromedarius*.

Osteometric studies were based on measurements described by Driesch² and Lasota-Moskalewska.³ The age of the sheep was determined using data from Lasota-Moskalewska's work, quoted after Kolda.⁴ For lack of appropriate data, the age at death of the camel could not be established.

The mammal bones indicated that the remains had been cuts of meat quartered from the fleshy parts of the carcass. No skull bones, teeth, or metatarsal bones were recorded. With regard to the sheep, thoracic vertebrae were the most numerous (14 fragments). Costa were also recorded in number (12 fragments). Apart from this, there were four fragments of humerus, two scapulae, two pelvic bones, two femurs and two tibia and calcaneus bones. Singular examples of radius, ulna, talus and patella bones were noted [Table 1]. As for the camel bones, femur fragments were the most numerous (10), but they actually represented a single crushed bone. Six costa bones were recorded and the same number of pelvic bones. Apart from this, there were four pieces of humerus, three ossa carpi and two ulna bones. A single piece of scapula was recorded, along with a radius bone and chopped off ulna, and patella [Table 2].

Almost all the long bones of both species could be attributed to young animals, which had not yet reached the age at which the diaphysis and epiphysis achieved full fusion. An evaluation of the ossification of epiphysial cartilage permitted the age at death of the animals to be established. The method is not precise, unfortunately, allowing little more than a determination of the

1 For a report on the excavations, cf. contribution by M. El-Tayeb in this volume.

2 A. Driesch A., "A guide to the measurement of animal bones from archaeological sites", *Peabody Museum Bulletins* 1 (1976).

3 A. Lasota-Moskalewska, *Podstawy archeozoologii. Szczątki ssaków* (PWN: Warszawa 1997).

4 J. Kolda, *Srovnávací anatomie zvířat domácích se zřetelem k anatomii člověka* (Brno, 1936).

Table 1. Bones of lamb and adult sheep from Tumulus 2, chambers 2 and 3

BONES	BONES OF LAMB (chamber 2)		BONES OF SHEEP (chambers 2 and 3)	
	No. of fragments	Comments	No. of fragments	Comments
<i>Cranium</i>				
<i>Mandibula</i>				
<i>Vertebrae</i>	8			
<i>Costa</i>	14	Marks of filleting	4	Marks of cutting
<i>Scapula</i>	1 right		1 left	Ld-105mm HS-225mm SLC-22mm GLP-16,5mm
<i>Humerus</i>	3 right	Diaphysis + epiphyses marks of cutting	1 left	Bp-47mm SD-18mm Bd-34mm GL-16,5mm marks of cutting
<i>Radius</i>	1 right	Without epiphysis Bd		
<i>Ulna</i>	1 right			
<i>Ossa carpi</i>				
<i>Ossa metacarpalia</i>				
<i>Pelvis</i>	1 right		1 left	
<i>Femur</i>	2 right	Diaphysis + epiphysis		
<i>Patella</i>	1			
<i>Tibia</i>	1 right	Without epiphyses	1 left	Bp-44mm SD-12mm Bd-27,5mm GL-250mm
<i>Talus</i>	1	Bd-17mm GL-28mm GLm-27mm		
<i>Calcaneus</i>	1 right	GL-50mm	1	GL-62mm
<i>Ossa metatarsalia</i>				
<i>Phalanx proximalis</i>				
<i>Phalanx media</i>				
<i>Phalanx distalis</i>				
TOTAL	35		9	

Table 2. Bones of camel from Tumulus 2, chambers 2 and 3

BONES	No. of fragments	Comments
<i>Cranium</i>		
<i>Mandibula</i>		
<i>Vertebrae</i>		Os sacrum
<i>Costa</i>	6	Marks of cutting
<i>Scapula</i>	1 left	Ld-190mm, HS-380mm, SLC-63mm, GLP-72mm
<i>Humerus</i>	4 right	Without epiphysis, marks of cutting
<i>Radius + Ulna</i>	1 right	
<i>Ulna</i>	2	Marks of chopping
<i>Ossa carpi</i>	3	
<i>Ossa metacarpalia</i>		
<i>Pelvis</i>	6	
<i>Femur</i>	10 left	Without epiphyses
<i>Patella</i>	1	
<i>Tibia</i>		
<i>Talus</i>		
<i>Calcaneus</i>		
<i>Ossa metatarsalia</i>		
<i>Phalanx proximalis</i>		
<i>Phalanx media</i>		
<i>Phalanx distalis</i>		
TOTAL	34	

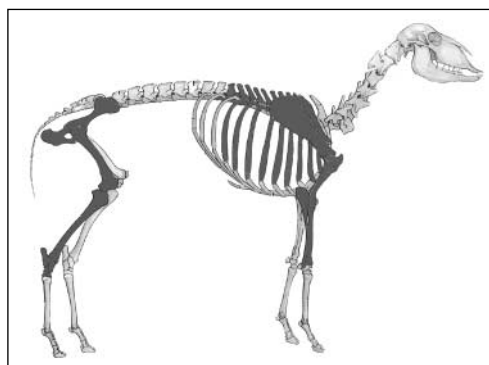


Fig. 1. Bones of lamb (darker color) found in Tumulus 2, chamber 2

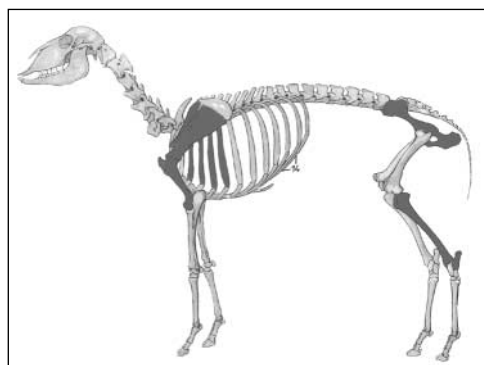


Fig. 2. Bones of older sheep (darker color) found in two chambers of Tumulus 2

age prior to which the animal was slaughtered. Even so, it permitted two individuals to be recognized among the sheep bones from the tumulus. One was a lamb slaughtered at about five months of age (Chamber 2) [Fig. 1]. The other animal was much older and bigger, although morphologically still immature [Fig. 2]. It was slaughtered at the age of 3-3.5 years. Its remains were found mostly in chamber 3 of the tomb with a few scattered in chamber 2.

The camel remains also came from most likely a single individual, which failed to reach morphological maturity. Lack of ap-

propriate data did not permit the age at death of the animal to be established. To judge by bone size, however, it could not have been a very young animal, more likely a juvenile approaching an adult in size.

Damages of twofold nature were noted on several of the examined bones. Some reflected processing by consumers, i.e., chopping on a radial bone of sheep and analogous cuts on the ulna and pelvis of a camel [Fig. 13]. Filleting marks, that is removing meat from the bones, were also noted as evidence of consumption practices. Such marks were seen on the costa bones of both the camel and sheep [Fig. 14].

RECAPITULATION

The assemblage of very well preserved animal bones coming from the three chambers of a tumulus grave on the cemetery in ez-Zuma was found not in anatomical order. An archeozoological analysis of the remains identified three species: two mammals (sheep and camel) and a bird (presumably chicken). The age and morphology of the animals were determined based on bony union (*synostosis*). It also proved possible to establish the actual number of animals.

The burial had been furnished with grave goods in the form of the meat of a lamb about five months of age, a young sheep and a juvenile camel. The carcasses had been butchered along body parts, retaining as an offering the most attractive cuts from the consumption point of view. The deposited meat comprised the right side of a lamb, left of a sheep and parts of both sides of a camel. It should be noted that the camel and sheep remains were deposited in different



Fig. 13. Chopping marks on camel pelvis bone
(Photo M. Osypińska)



Fig. 14. Cutting marks on camel costa bone
(Photo M. Osypińska)

chambers. The lamb was found in chamber 2, while the bones of sheep and camel were discovered in both chambers 2 and 3 of the tomb. The finds from the fill in chamber 1 (one camel bone and bird bone) should be considered as doubtful, tenably representing a secondary deposit.

The morphological examination of the sheep indicated that the species was very near to animals identified at other sites dated to the same period (cemetery on Saffi island). A comparison of osteometric data [Table 3] reveals that the same kind of sheep, the thin-tailed Sudan Desert type, was bred in medieval Dongola, as well as in modern times.⁵

Marks observed on the bones leave no doubt that the animal carcasses had been carefully quartered and filleted, obviously preparing the choicest cuts of meat. The filleting on the costa bones of sheep and camel is interesting to note as it suggests that the meat had been separated from the bone before being deposited in the grave. Perhaps the animal remains were not so much gifts for the dead as leftovers from a funeral banquet.⁶

It would also explain why the remains were found in different chambers and not in anatomical order.

Faunal remains from one of the tumuli in the ez-Zuma necropolis were at once typical and exceptional. Bones of small ruminants, like sheep or goat, are fairly common on archaeological sites. Indeed, there is practically no post-Meroitic cemetery in the Fourth Cataract region where bones of these animals would not be found in the graves. Yet these are most often innumerable assemblages, consisting of a few bones only and the ez-Zuma material is relatively abundant in this respect. It represents two individual animals, whose carcasses were butchered specifically for consumption purposes. The presence of camel bones, evidently intended for consumption as well, is definitely a much rarer find. Interestingly, the considerable demand for choice meat in this case was satisfied not with beef, but with camel meat.

Further research at the cemetery in ez-Zuma should prove of significance for studies of the animal population and their role in the funerary rites.

Table 3. Selected osteometric values for sheep from two Post-Meroitic cemeteries (Saffi and ez-Zuma), Kom A in Old Dongola (Christian period) and modern animals from the Dongola Reach (all research by the author working for PCMA expeditions to Uli and Saffi islands and Old Dongola)

Bone	Measurement	ez-Zuma	Saffi	Old Dongola	modern
<i>Scapula</i>	GLP	31 mm	31 mm	31mm	-
<i>Scapula</i>	SLC	15 mm	16 mm	18 mm	-
<i>Talus</i>	GLm	27 mm	26 mm	27 mm	27.5mm
<i>Talus</i>	GLI	28 mm	27 mm	28 mm	30mm
<i>Talus</i>	Bd	17 mm	17 mm	18 mm	18mm
<i>Calcaneus</i>	GL	50 mm	47 mm	64 mm	57mm

5 H. Epstein, The origin of the domestic animals of Africa (Leipzig 1971.); cf. M. Osypińska, "Animal bone remains from Old Dongola", *PAM XV, Reports 2003* (2004), 224-230.

6 P. Lenoble, "A preliminary study of 'burial customs' of religious and political significance during late Meroitic times in the Sahelian Nile region, S.A.S. Occasional Papers (Khartoum 1987); M. El-Tayeb, "Burial customs of Post-Meroitic Makuria, *GAMAR I* (1998), 49-51.